

Intramyocardial and intracoronary autologous bone marrow-derived mesenchymal stromal cell treatment in chronic severe dilated cardiomyopathy

SZE-PIAW CHIN¹, ALFRED C. POEY², CHEE-YIN WONG³, SAU-KONG CHANG², CHIANG-SOO TAN², MEI-THENG NG³, KEE-HOCK CHEW², KAI-HUAT LAM⁴ & SOON-KENG CHEONG⁵

¹Mawar Hospital, Negeri Sembilan, Malaysia, ²Penang Adventist Hospital, Penang, Malaysia, ³Cytopeutics, Selangor, Malaysia, ⁴Assunta Hospital, Selangor, Malaysia, and ⁵Tunku Abdul Rahman University, Selangor, Malaysia

Abstract

Background aims. Mesenchymal stromal cells (MSC) may improve cardiac function following myocardial infarction. MSC can differentiate into cardiomyocytes and endothelial cells while exerting additional paracrine effects. There is limited information regarding the efficacy of route for MSC treatment of severe dilated cardiomyopathy (DCM). The aim of this study was to demonstrate the clinical safety, feasibility and efficacy of direct intramyocardial and intracoronary administration of autologous bone marrow-derived MSC treatment for no-option patients with chronic severe refractory DCM. **Methods.** Ten symptomatic patients with DCM and refractory cardiac function, despite maximum medical therapy, were selected. Five had ischemic DCM deemed unlikely to benefit from revascularization alone and underwent bypass operations with concurrent intramyocardial MSC injection (group A). Two patients had previous revascularization and three had non-ischemic DCM and received intracoronary MSC injection (group B). **Results.** Group A and B patients received $0.5\text{--}1.0 \times 10^6$ and $2.0\text{--}3.0 \times 10^6$ MSC/kg body weight, respectively. All patients remained alive at 1 year. There were significant improvements from baseline to 6 and 12 months in left ventricular ejection fraction and other left ventricular parameters. Scar reduction was noted in six patients by 12 months. **Conclusions.** Autologous bone marrow MSC treatment is safe and feasible for treating chronic severe refractory DCM effectively, via intracoronary or direct intramyocardial administration at prescribed doses.

Key Words: dilated cardiomyopathy, intracoronary injection, intramyocardial injection, mesenchymal stromal cell

Introduction

Dilated cardiomyopathy (DCM) may be ischemic or non-ischemic in origin, the latter mainly caused by infection, immune mediation or metabolism (1). DCM carries a very poor prognosis, with 5-year survival estimated at 60% or less (2). Mortality results from sudden arrhythmogenic cardiac arrest or progressive heart failure, which are related to the fibrotic scarring that accompanies the dilatation (3).

Procedures to revascularize the heart, such as percutaneous transcatheter angioplasty (PTCA) and coronary artery bypass graft (CABG) operations, may revitalize viable and hibernating myocardium but normally do not significantly improve the global function, especially when extensive loss of muscle and scarring exists (4). Similarly, for patients with non-ischemic DCM, the progressive dilatation and

weakening of the heart persists even after resolution of the underlying cause. Several possibilities exist for correcting DCM, including biventricular pacing, surgical ventricular restoration, insertion of left ventricular (LV) assist devices and heart transplantation (1). However, these options are suitable only for a very small number of patients who satisfy the criteria; for the vast majority of symptomatic severe DCM patients, there are still no practical treatment options (5).

Cell therapy is a promising innovative therapy for treating heart failure (6). Unselected bone marrow (BM) mononuclear cells (MNC) have been used recently in acute myocardial infarction (MI) with some success (7,8). However, the results are not consistent with studies showing no benefit at all, or loss of advantage after a period of follow-up (9,10).

Conversely, a subpopulation of BM-derived mesenchymal stromal cells (MSC) has demonstrated an ability to improve cardiac function, functional score and wall motion abnormality while reducing scarring and the perfusion defect (11,12). MSC can be differentiated into cardiomyocytes and endothelial progenitor cells, and may regulate inflammation and fibrosis (13,14). Nevertheless, studies employing MSC for ischemic DCM are few and the majority of studies have evaluated MSC soon after revascularization and in patients who experienced MI less than 3 months before MSC injection. This has led to difficulty in elucidating the true contribution of MSC to the recovery of myocardial function. Furthermore, to our knowledge there has been no study that has investigated the use of MSC in non-ischemic DCM (15).

We have previously demonstrated that cryopreserved MSC can be transported safely to outlying hospitals for direct intramyocardial injection (16). The aim of this study was to evaluate the feasibility and safety of autologous BM MSC treatment in chronic severe DCM by direct intramyocardial injection or intracoronary infusion at specific cell doses, and evaluate the efficacy of such routes and dose compared with the progression of cardiac function prior to treatment.

Methods

Patient selection

The study was approved by the local ethics committee and all patients signed a consent form. The study was registered under Malaysia's National Medical Research Register No. 0582.

Between February 2008 and February 2009, three cardiology clinics screened all clinical heart failure patients [New York Heart Association (NYHA) functional classes II–IV] with documented evidence of LV dysfunction and dilatation despite optimal anti-failure medications. Patients with an ejection fraction of less than 35% and without significant change on at least two occasions in the previous 6 months were considered. Patients were excluded if they (i) had improved significantly since revascularization and/or commenced medications in the previous 6 months and (ii) were deemed likely to benefit from revascularization alone or satisfy the criteria for cardiac resynchronization therapy. Other exclusions were severe renal impairment (serum creatinine greater than 200 mmol/L), liver impairment (serum transaminases greater than three times the upper limit of normal), irreversible coagulopathies, any prior malignancies and active infections, including viral hepatitis and human immunodeficiency virus (HIV).

To determine whether patients might benefit from revascularization, they underwent baseline cardiac magnetic resonance imaging (MRI) to determine the number of viable LV segments. Patients with less than seven (out of 14) viable segments present were regarded as unlikely to benefit from revascularization alone, based upon previous studies that have shown only modest improvement in ejection fraction of less than five percentage points (4).

Twenty consecutive patients with refractory symptomatic severe heart failure were considered. Eight patients demonstrated significant viable myocardium and were referred for initial revascularization. Two patients had bundle branch block on electrocardiography and were referred for consideration for cardiac resynchronization therapy. Of the remaining 10 patients who were eligible [all male, mean age 58 years, left ventricular ejection fraction (LVEF) 26.6%, NYHA IV], all agreed to participate in the study. Five patients with coronary artery disease deemed unlikely to benefit from revascularization alone were assigned to MSC intramyocardial injection with concurrent CABG operation (group A), while another five patients with patent coronary vessels (including non-ischemic DCM and those with previously successful revascularization who had then remained symptomatic) were assigned to slow intracoronary MSC infusion (group B) (Figure 1).

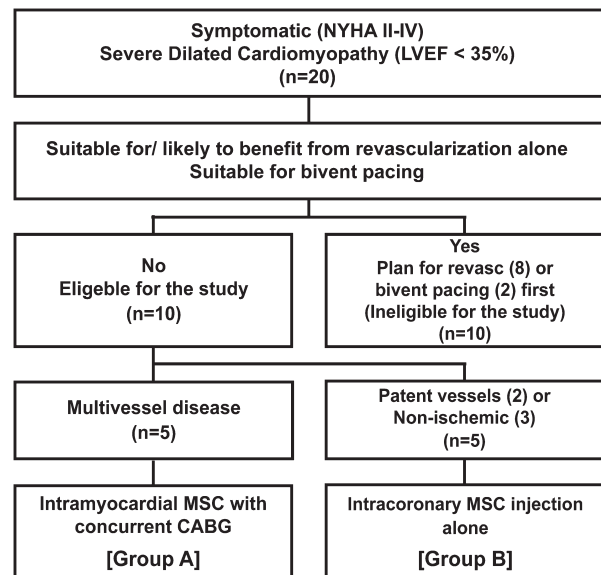


Figure 1. Of 20 patients recruited for the study, only 10 were eligible. Five patients had multivessel coronary disease and were assigned a CABG operation with concurrent intramyocardial MSC injection (group A). Five patients with patent coronary vessels were assigned to intracoronary infusion of MSC, of whom two patients had had previous revascularization procedures with patent vessels, and three patients had non-ischemic DCM (group B).

MSC culture and storage

These methods have been described previously (16). Briefly, 20 mL of BM aspirate (BMA) were obtained from the iliac crest of each patient and processed within 12 h. MSC were isolated based on Ficoll-Paque density-gradient centrifugation and adherence to a plastic surface. MSC were cultured in Dulbecco's modified Eagle's medium containing low glucose (DMEM-LG; Gibco, Grand Island, NY, USA) supplemented with 10% autologous serum, 100 U/mL penicillin, 100 mg/mL streptomycin, 250 ng/mL amphotericin B and 2 mM GlutaMAX (Gibco). The cultures were maintained at 37°C in a humidified atmosphere of 5% CO₂ and 95% air.

After 3 days, non-adherent cells were discarded. Fresh culture medium was replaced every few days until cells reached confluence. The adherent cells were harvested after briefly incubating with TrypLE Select (Gibco) and replated at low density, thus expanding the population of MSC. Once the required number of cells was reached, MSC were harvested and cryopreserved. Small volumes of the cell culture media used for MSC culture were sent for bacterial and fungal tests. MSC were confirmed by immunophenotyping and their differentiation abilities, as described previously (17).

One day before MSC injection, cryopreserved MSC were transferred to the hospital in a cryoshipper. At the operating theatre, the cells were thawed in a 37°C warm water bath, washed once and then resuspended using sterile 0.9% normal saline solution before being transferred into a syringe for intramyocardial injection or intracoronary infusion.

Intramyocardial MSC injection

For patients in group A, the presence and extent of scarred or non-viable areas detected on baseline imaging was confirmed visually at open heart surgery. Following completion of coronary grafting, an aortic cross clamp was released allowing blood to fill the ventricle. MSC suspension was then injected around the circumference of the scar tissue in a (18). Typically 15–20 sites 1–2 cm apart were injected using a 27-G needle. At each site, 0.5–1.0 mL MSC suspension was injected and light pressure applied after withdrawal of the needle. The cell dosage range was 0.5–1.0 × 10⁶ MSC/kg, based on a patient's weight and number of affected myocardial segments.

Intracoronary MSC infusion

For patients in group B, after confirming the patency of the coronary artery by conventional coronary angiography, a guiding catheter was engaged to pass a small 2.5-mm × 10-mm balloon mounted over-

the-wire (19). When the balloon was in place within the stent or at the site of previous occlusion, the wire was withdrawn and the syringe containing the suspended MSC was fixed. The balloon was inflated at 2–3 atmosphere (ATM) to partially occlude flow for injection of 2–3 mL suspended MSC through the lumen. The balloon remained inflated for 90–120 s, and was then deflated for a further 90–120 s. The whole process was repeated two to three times until all MSC had been infused. The total number of cells injected ranged between 2.0 × 10⁶ and 3.0 × 10⁶ MSC/kg based on a patient's weight and number of affected myocardial segments. After the balloon was withdrawn, a final angiography was performed to ensure that there were no complications.

Follow-up

Patients remained in hospital in the cardiothoracic intensive care unit or coronary care unit for at least 24 h, to be monitored by telemetry for any ventricular arrhythmias. At the end of the hospital stay, patients had an echocardiography to exclude pericardial effusions. They were required to return for follow-up at 6 weeks, 3 months, 6 months and 12 months. Echocardiography to evaluate LVEF, left ventricular end diastolic diameter (LVEDD), left ventricular end systolic diameter (LVESD) and interventricular septal thickness at diastole (IVSD) was performed at each visit and compared with baseline readings. A cardiac MRI with gadolinium delay enhancement was performed at baseline and 12 months to look for scarring and non-viable areas as well as LV volume, dimensions and function.

Statistical methods

The patients' LV parameters on echocardiography prior to MSC treatment served as controls for the changes noted after treatment. Echocardiography, cardiac MRI and functional evaluation were evaluated independently and data were stored with SPSS 14. Parametric data were expressed as mean ± 1 standard deviation (1 SD). Comparisons with baseline were performed using paired *t*-tests, while comparisons between groups used independent *t*-tests. Further comparisons were made with results of the same patients in the 6 months prior to recruitment. No corrections were done for multiple comparisons.

Results*Patient baseline*

All patients were male. The mean age was 58.8 ± 9.1 years. The mean NYHA functional score was 3.8 and mean LVEF was 26.5 ± 6.7%. Change in LVEF in

the 6 months prior to treatment was 0.9 ± 5.2 . Six patients had multiple MI and multiple coronary vessel involvement. The left anterior descending artery territory was involved in all patients with MI. Five patients were smokers or ex-smokers, all patients had co-morbid diabetes, dyslipidemia and hypertension, and four patients had had previous ischemic strokes. All patients were on optimal medical therapy at maximally tolerated doses, including angiotensin-converting enzyme (ACE) inhibitors, beta receptor antagonists, aldosterone antagonists, diuretics, lipid-lowering drugs and anti-platelet agents. Five patients received MSC by direct intramyocardial injection with concurrent CABG (group A) and five patients received by MSC by slow intracoronary infusion (group B).

All patients had functional mitral regurgitation and LV dilatation [mean left ventricular end diastolic volume (LVEDV) 244.9 ± 86 mL, mean LVEDD 68.8 ± 10.5 mm]. Except for LVEF, group B patients had worse baseline ventricular parameters compared with group A (LVEDV 283.6 ± 94.5 mL versus 206.2 ± 62.8 mL, $P < 0.05$; LVEDD 73.2 ± 11.6 mm versus 64.5 ± 13.6 mm, $P < 0.05$) (Table I).

Autologous MSC culture and injection

MSC were isolated successfully from all patients and were expanded to the desired number within 1 month with at least 90% viability. The duration from cryopreservation to day of surgery was 5–30 days, while the duration from cell resuspension to injection was between 1 to 3 h. Patients in group A received an average of 46×10^6 MSC or approximately 0.6×10^6 cells/kg body weight via intramyocardial injection with concurrent CABG. Patients in group B

received 150×10^6 MSC or approximately 2×10^6 cells/kg body weight via slow intracoronary infusion.

Referring to the patients' histories, the mean time from last MI episode to MSC transplantation was 18.7 months ± 8.3 months. For patients with prior revascularization, the mean time from last MI to revascularization was 13 months and the mean time from revascularization to MSC transplantation was 8.75 months.

MSC safety and feasibility of implantation by direct intramyocardial injection and intracoronary route

All patients tolerated the procedure well. MSC were successfully administered in all cases. There were no immediate post-procedural complications, such as no-reflow or raised cardiac enzymes following intracoronary implantation, and no pericardial bleeding following direct intramyocardial injection. There were no arrhythmias during the 24-h observation on the coronary care units. Patients were discharged well and all patients remained alive after the minimum 12-month follow-up period.

Comparison of parameters before and after MSC treatment

The changes in LV parameters at 6 months post-MSC treatment were compared with changes in the 6 months prior to baseline MSC treatment. The changes in LV parameters at 6 months post-treatment were LVEF $19.3 \pm 9.3\%$, LVEDV -48.7 ± 43.2 mL, left ventricular end systolic volume (LVESV) -57.3 ± 35.6 mL, LVEDD -8.6 ± 7.2 mm, and LVESD -11.4 ± 7.7 mm. Correspondingly, the changes in LV parameters in the 6 months prior to treatment

Table I. Baseline clinical data and echocardiographic LV parameters of all patients with DCM and according to route of MSC administration: direct intramyocardial injection (group A) or intracoronary infusion (group B).

	Total (n = 10)	Group A (n = 5)	Group B (n = 5)	P-value
Age (years)	58.8 ± 9.1	59.4 ± 4.9	58.2 ± 12.2	0.85
Time from MI to MSC injection (months)	18.7 ± 8.2	18.0 ± 8.5	19.5 ± 9.0	0.81
Diabetes mellitus (n)	9	5	4	0.5
Smoker (n)	7	3	4	0.5
Hypertension (n)	10	5	5	1.0
Dyslipidemia (n)	10	5	5	1.0
Stroke (n)	4	3	1	0.26
Beta-blocker (n)	10	5	5	1.0
ACE inhibitors (n)	10	5	5	1.0
Spirolactone (n)	10	5	5	1.0
Furosemide (n)	10	5	5	1.0
LVEF (%)	26.5 ± 6.7	26.1 ± 7.9	26.7 ± 6.2	0.87
LVEDV (mL)	244.9 ± 86.0	206.2 ± 7.9	283.6 ± 94.6	0.17
LVESV (mL)	173.7 ± 79.2	148.4 ± 72.8	199.0 ± 85.0	0.34
LVEDD (mm)	68.8 ± 10.5	64.5 ± 8.3	73.2 ± 11.6	0.21
LVESD (mm)	58.7 ± 11.5	53.3 ± 8.9	64.1 ± 12.1	0.15
IVSD (mm)	11.2 ± 2.5	10.5 ± 2.1	11.9 ± 2.9	0.41

were LVEF $0.93 \pm 5.2\%$, LVEDV 3.6 ± 6.2 mL, LVESV 1.4 ± 6.2 mL, LVEDD 0.1 ± 1.4 mm, and LVESD -0.5 ± 1.9 mm (Figure 2). The paired differences in LV changes post-treatment and prior to treatment were all $P < 0.02$.

Cardiac MRI also showed significant improvements in LVEF from baseline to 12 months ($29.9 \pm 7.1\%$ versus $50.0 \pm 9.2\%$; $P < 0.02$). Complete resolution of full thickness scarring in at least one myocardial segment, as assessed by delay-enhanced cardiac resonance imaging, was noted in six out of 10 patients by 12 months.

Intracoronary MSC treatment of non-ischemic DCM

There were three patients with non-ischemic DCM (one from thyrotoxicosis and two idiopathic). Mean LVEF ± 1 SD was $24.5 \pm 5.3\%$ at baseline, $33.3 \pm 9.0\%$ at 6 months and $39.6 \pm 7.7\%$ at 12 months. NYHA reduced from IV to II for the two patients with idiopathic DCM, and from IV to III for the patient with previous thyrotoxicosis. There were only modest reductions in ventricular volumes and diameter. None of the changes was statistically significant because of the small numbers.

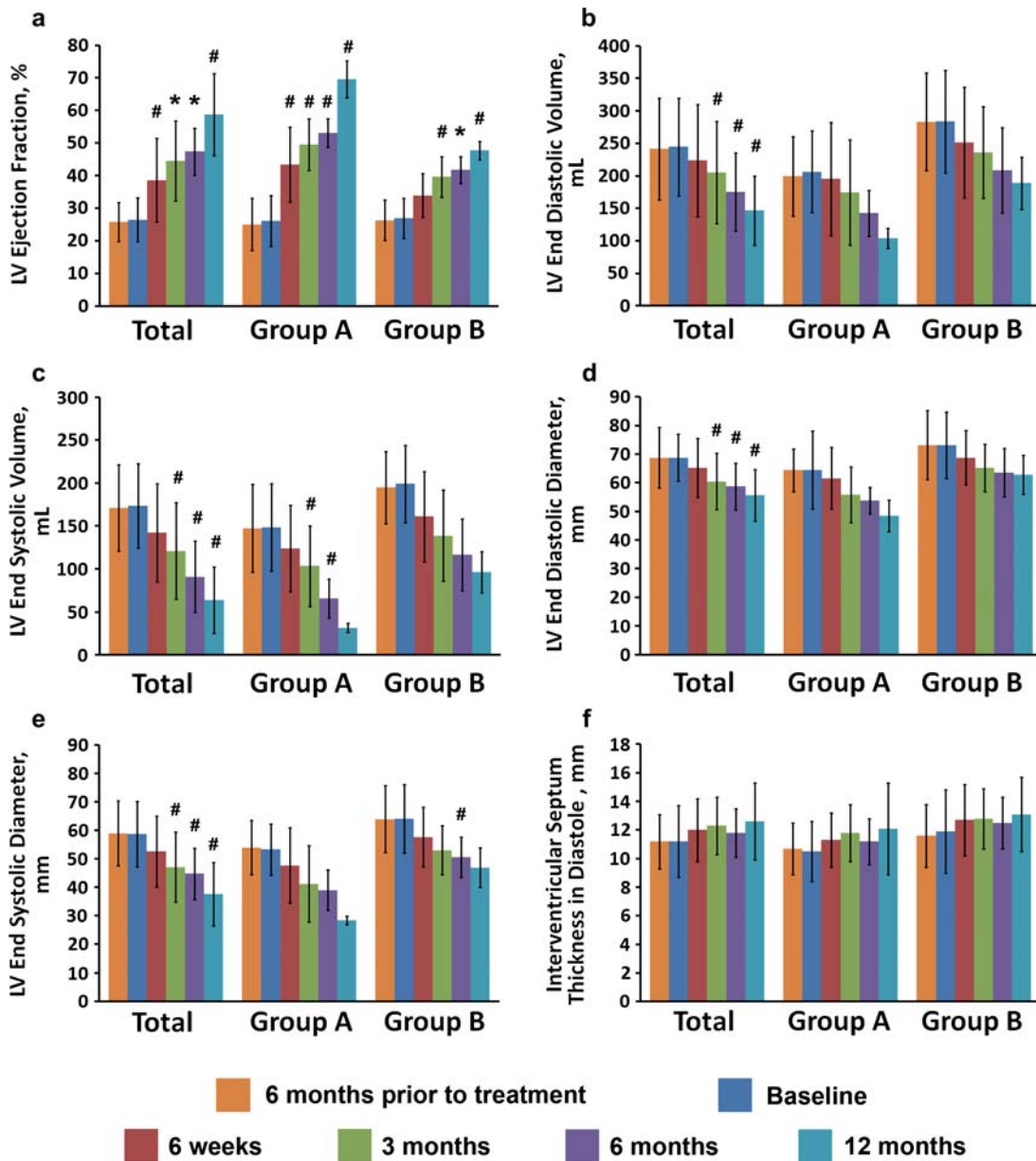


Figure 2. LV parameters by echocardiography at 6 months prior to treatment, baseline, and 6 weeks, 3 months, 6 months and 12 months post-MSC direct intramyocardial (group A) and intracoronary (group B) injection. Values are expressed as mean ± 1 SD. Means compared with baseline using paired Student's *t*-test, where # denotes a *P*-value less than 0.05 compared with baseline and * denotes a *P*-value less than 0.01 compared with baseline. A *P*-value of less than 0.05 was considered statistically different.

Discussion

Our results have shown that it is possible to isolate and expand MSC from patients with severe DCM even with existing co-morbidities such as multivessel coronary disease, diabetes, hypertension, dyslipidemia and active smoking. Hence it would be feasible to provide autologous MSC treatment for DCM, an important option at such an early development of this promising therapy. This safety consideration is very important considering the fact that MSC is being injected directly into the myocardium, and data are now emerging that allogeneic MSC may in fact elicit an immunogenic reaction (20).

We have also demonstrated that, for patients deemed conventionally unlikely to benefit from revascularization because of significant non-viability of the myocardium, the concurrent treatment of MSC injection with CABG results in significant improvement of LV function. Indeed, even for patients where cardiac function remains poor after revascularization, adjunctive intracoronary administration of MSC at higher doses may still confer benefit. The improvements, both clinically and objectively, were apparent from about 6 months after treatment. The improvements to LV parameters after MSC treatment were significant compared with the period between revascularization and receiving MSC injection. These changes before and after MSC injection suggest that MSC confers additional benefits beyond revascularization alone. Other authors have also demonstrated that patients with severe ischemic DCM may benefit from administration of unselected BM MNC (21,22). These improvements may persuade surgeons reluctant to operate on patients with severe cardiac dysfunction because of perceived lack of benefit. It has been accepted that, for patients with more than 50% non-viable segments, LVEF less than 35% and LV end systolic volumes more than 140 mL, any improvement to LV function after revascularization is modest and short-lived (23,24). This is supposedly so even in the presence of significant hibernating myocardium (25).

For many of the patients, in either arm, the improvements to LV function were noted even earlier than 6 months. This early benefit is likely to be mediated via paracrine actions of MSC that assist and augment repair while inhibit remodeling (26). One of the mechanisms may be the control of inflammation and inhibition of fibrosis formation following acute injury. Heart failure itself is an inflammatory process, with raised levels of C-reactive protein, catecholamines, interleukins and tumor necrosis factor, among others (5). It is thought that the inflammatory cytokines, in addition to organ tissue repair by fibrosis and remodeling, may induce apoptosis, which

may be inhibited by MSC. Symptomatic improvement without significant underlying change in LV function was noted in most patients at 6 weeks.

Importantly, our results suggest that MSC may be exerting a more permanent or persistent active biologic effect in addition to the early transient paracrine effect. First, the echocardiographic findings demonstrate a consistent and continuing improvement in all parameters up to 12 months, following a single dose injection of cells. Indeed, there is an interim period of about 3–6 months when the effect seems to plateau, only to pick up again between 6 to 12 months. We suspect that this watershed period could be because of the failure of adhered cells to engraft and remain viable, leading to a loss of paracrine effect, while the small number of engrafted cells multiply, differentiate and mature slowly at first. Second, there appears to be resolution of full thickness scarring, as evidenced by cardiac MRI with gadolinium-delayed enhancement studies at 12 months. The resolution of full thickness scarring along with increased thickness of the LV wall again suggests the restoration potential of stem cell therapy. However, it cannot be confirmed whether the restoration was the result of MSC differentiation into cardiomyocytes, MSC activation of resident cardiac stem cells and recruitment of circulating stem cells, or other mechanisms. It is likely that all three mechanisms play a role (26).

This novel therapy is all the more important given that patients were deemed initially unlikely to benefit from revascularization alone. There has been one other study using intracoronary transplantation of autologous BM MSC for ischemic DCM with a significant reversible perfusion defect (27). To our knowledge, this is the first use of MSC in chronic severe DCM with extensive non-viability. Despite receiving less MSC per body weight, patients who obtained MSC by direct intramyocardial injection with concurrent revascularization demonstrated earlier and more significant improvement than those who obtained MSC via intracoronary infusion. The cell dose is therefore appropriate when administered intramyocardially, whereas it may be possible to use even more cells when administered intra-arterially. This remains to be proven but may be important, especially when dealing with non-ischemic DCM with extensive fibrosis.

However, it must be noted that the rate of improvement was not universal and was not related to the dose of MSC or severity of disease at baseline. Of the 10 patients treated, one patient (non-ischemic thyrotoxic-induced DCM) remained symptomatic and continued to rely heavily on anti-failure medications. The patient's symptoms may have been because of co-morbid hepatic failure,

as his LVEF had improved from 30% to 39% at 12 months. The patient with thyrotoxicosis was one of three patients with non-ischemic DCM. These patients had among the lowest LVEF and largest LV diameters and volumes (data not shown). The other two with idiopathic DCM showed significant improvement in symptoms and LVEF and modest reduction in LV volumes. Even though unselected BM MSC have been tried in patients with non-ischemic DCM with some improvements (28), this is the first time, to our knowledge, that autologous MSC has been used for this group of patients. The results are encouraging and suggest potential benefit for selected patients.

This study is limited by the small number of patients recruited. This was because of the strict exclusion criteria that rejected any patients for whom other, more acceptable, methods of treatment existed. The group was also not homogeneous, with three patients with non-ischemic DCM while two patients had had prior revascularization. Nevertheless the progression of heart failure and remodeling in DCM were similar (3). The study also lacked a control arm; instead patients acted as their own controls, by comparing the changes in LV function after treatment with changes in the 6 months prior to treatment. The study had a short follow-up period. However, when we first planned the project, we estimated that the 1-year survival for patients with NYHA IV and an ejection fraction less than 30% would be between 25% and 50% (2). Hence we did not expect to follow-up beyond 1 year or for the patients to all still be alive at the end of follow-up. A final important limitation, which sets back most clinical studies, was the lack of ability to determine the true fate of the transplanted MSC. As the cells were autologous and not genetically altered, and no markers were attached for this clinical study, we were not able to track the MSC.

Taking into account these limitations, we wish to conclude that the study has demonstrated it is feasible to obtain sufficient viable BM MSC for autologous treatment of patients with severe chronic refractory DCM. The treatment, by direct intramyocardial injection or intracoronary infusion at prescribed doses, is safe and feasible and appears to confer benefit regarding symptoms and LV function improvement in selected patients with chronic and refractory symptoms despite optimal therapy. Early benefits may have been predominantly because of paracrine effects, while later improvements, including scar resolution and increased myocardial thickness, were due to myocardial regeneration. Larger trials are warranted to confirm these benefits seen in very ill patients with no other practical options.

Declaration of interest: The authors report no conflicts of interest. The authors alone are responsible for the content and writing of the paper.

References

- Swedberg K, Cleland J, Dargie H, Drexler H, Follath F, Komajda M, et al. Guidelines for the diagnosis and treatment of chronic heart failure: executive summary (update 2005): The Task Force for the Diagnosis and Treatment of Chronic Heart Failure of the European Society of Cardiology. *Eur Heart J*. 2005;26:1115–40.
- Levy D, Kenchaiah S, Larson MG, Benjamin EJ, Kupka MJ, Ho KK, et al. Long-term trends in the incidence of and survival with heart failure. *N Engl J Med*. 2002;347:1397–402.
- Mann DL, Bristow MR. Mechanisms and models in heart failure: the biomechanical model and beyond. *Circulation*. 2005;111:2837–49.
- Bax JJ, Visser FC, Poldermans D, Elhendy A, Cornel JH, Boersma E, et al. Relationship between preoperative viability and postoperative improvement in LVEF and heart failure symptoms. *J Nucl Med*. 2001;42:79–86.
- Lipiecki J, Durel N, Ponnouaille J. Which patients with ischemic heart disease could benefit from cell replacement therapy? *Eur Heart J*. 2006;8(Suppl H):H3–7.
- Boyle AJ, Schulman SP, Hare JM, Oettgen P. Stem cell therapy for cardiac repair: ready for the next step. *Circulation*. 2006;114:339–52.
- Abdel-Latif A, Bolli R, Tleyjeh IM, Montori VM, Perin EC, Hornung CA, et al. Adult bone marrow-derived cells for cardiac repair: a systematic review and meta-analysis. *Arch Intern Med*. 2007;167:989–97.
- Lipinski MJ, Biondi-Zoccai GG, Abbate A, Khianey R, Sheiban I, Bartunek J, et al. A collaborative systematic review and meta-analysis of controlled clinical trials. *J Am Coll Cardiol*. 2007;50:1761–7.
- Janssens S, Dubois C, Bogaert J, Theunissen K, Deroose C, Desmet W, et al. Autologous bone marrow-derived stem-cell transfer in patients with ST-segment elevation myocardial infarction: double-blind, randomised controlled trial. *Lancet*. 2006;367:113–21.
- Meyer GP, Wollert KC, Lotz J, Steffens J, Lippolt P, Fichtner S, et al. Intracoronary bone marrow cell transfer after myocardial infarction: eighteen months' follow-up data from the randomized, controlled BOOST (BONemarrOw transfer to enhance ST-elevation infarct regeneration) trial. *Circulation*. 2006;113:1287–94.
- Chen SL, Fang WW, Ye F, Liu YH, Qian J, Shan SJ, et al. Effect on left ventricular function of intracoronary transplantation of autologous bone marrow mesenchymal stem cell in patients with acute myocardial infarction. *Am J Cardiol*. 2004;94:92–5.
- Katritsis DG, Sotiropoulou PA, Karvouni E, Karabinos I, Korovesis S, Perez SA, et al. Transcoronary transplantation of autologous mesenchymal stem cells and endothelial progenitors into infarcted human myocardium. *Catheter Cardiovasc Interv*. 2005;65:321–9.
- Toma C, Pittenger MF, Cahill KS, Byrne BJ, Kessler PD. Human mesenchymal stem cells differentiate to a cardiomyocyte phenotype in the adult murine heart. *Circulation*. 2002;105:93–8.
- Ghannam S, Bouffi C, Djouad F, Jorgensen C, Noel D. Immunosuppression by mesenchymal stem cells: mechanisms and clinical applications. *Stem Cell Res Ther*. 2010;1:2 doi:10.1186/scrt2.

15. Guarita-Souza CL, de Carvalho KAT, Francisco JC, Simeoni R, Faria-Neto JR. Cellular transplantation for the treatment of non-ischaemic dilated cardiomyopathies. *Eur Heart J Suppl.* 2008;10:K7–10.
16. Chin SP, Poey AC, Wong CY, Chang SK, Teh W, Mohr TJ, et al. Cryopreserved mesenchymal stromal cell treatment is safe and feasible for severe dilated ischemic cardiomyopathy. *Cytotherapy.* 2010;12:31–7.
17. Wong CY, Cheong SK, Mok PL, Leong CF. Differentiation of human mesenchymal stem cells into mesangial cells in post-glomerular injury murine model. *Pathology.* 2008;40:52–7.
18. Law PK, Chin SP, Hung HD, Nguyen TN, Feng QZ. Delivery of biologics for angiogenesis and myogenesis. In: Nguyen TN, Colombo A, Hu D, Grines CL, Saito S. *Practical Handbook of Advanced Interventional Cardiology.* 3rd ed. New York: Blackwell; 2008. p. 583–95.
19. Sherman W, Martens TP, Viles-Gonzalez JF, Siminiak T. Catheter-based delivery of cells to the heart. *Nat Clin Pract Cardiovasc Med.* 2006;3(Suppl 1):S57–64.
20. Nauta AJ, Westershuis G, Kruisselbrink AB, Lurvink EG, Willemze R, Fibbe WE. Donor derived mesenchymal stem cells are immunogenic in an allogeneic host and stimulate donor graft rejection in a nonmyeloablative setting. *Blood.* 2006;108:2114–20.
21. Perin EC, Dohmann HF, Borojevic R, Silva SA, Sousa AL, Mesquita CT, et al. Transendocardial autologous bone marrow cell transplantation for severe, chronic ischemic heart failure. *Circulation.* 2003;107:2294–302.
22. Assmus B, Honold J, Schächinger V, Britten MB, Fischer-Rasokat U, Lehmann R, et al. Transcoronary transplantation of progenitor cells after myocardial infarction. *N Engl J Med.* 2006;355:1222–32.
23. Bax JJ, Poldermans D, Elhendy A, Cornel JH, Boersma E, Rambaldi R, et al. Improvement of left ventricular ejection fraction, heart failure symptoms and prognosis after revascularization in patients with chronic coronary artery disease and viable myocardium detected by dobutamine stress echocardiography. *J Am Coll Cardiol.* 1999;34:163–9.
24. Schinkel AF, Poldermans D, Rizzello V, Vanoverschelde JL, Elhendy A, Boersma E, et al. Why do patients with ischaemic cardiomyopathy and a substantial amount of viable myocardium not always recover in function after revascularization? *J Thorac Cardiovasc Surg.* 2004;127:385–90.
25. Bax JJ, Schinkel AF, Boersma E, Elhendy A, Rizzello V, Maat A, et al. Extensive left ventricular remodeling does not allow viable myocardium to improve in left ventricular ejection fraction after revascularization and is associated with worse long-term prognosis. *Circulation.* 2004;110:II18–22.
26. Dimmeler S, Zeiher AM, Schneider MD. Unchain my heart: the scientific foundations of cardiac repair. *J Clin Invest.* 2005;115:572–83.
27. Chen S, Liu Z, Tian N, Zhang J, Yei F, Duan B, et al. Intracoronary transplantation of autologous bone marrow mesenchymal stem cells for ischemic cardiomyopathy due to isolated chronic occluded left anterior descending artery. *J Invasive Cardiol.* 2006;18:552–6.
28. Gao LR, Wang ZG, Zhu ZM, Fei YX, He S, Tian HT, et al. Effect of intracoronary transplantation of autologous bone marrow-derived mononuclear cells on outcomes of patients with refractory chronic heart failure secondary to ischemic cardiomyopathy. *Am J Cardiol.* 2006;98:597–602.